

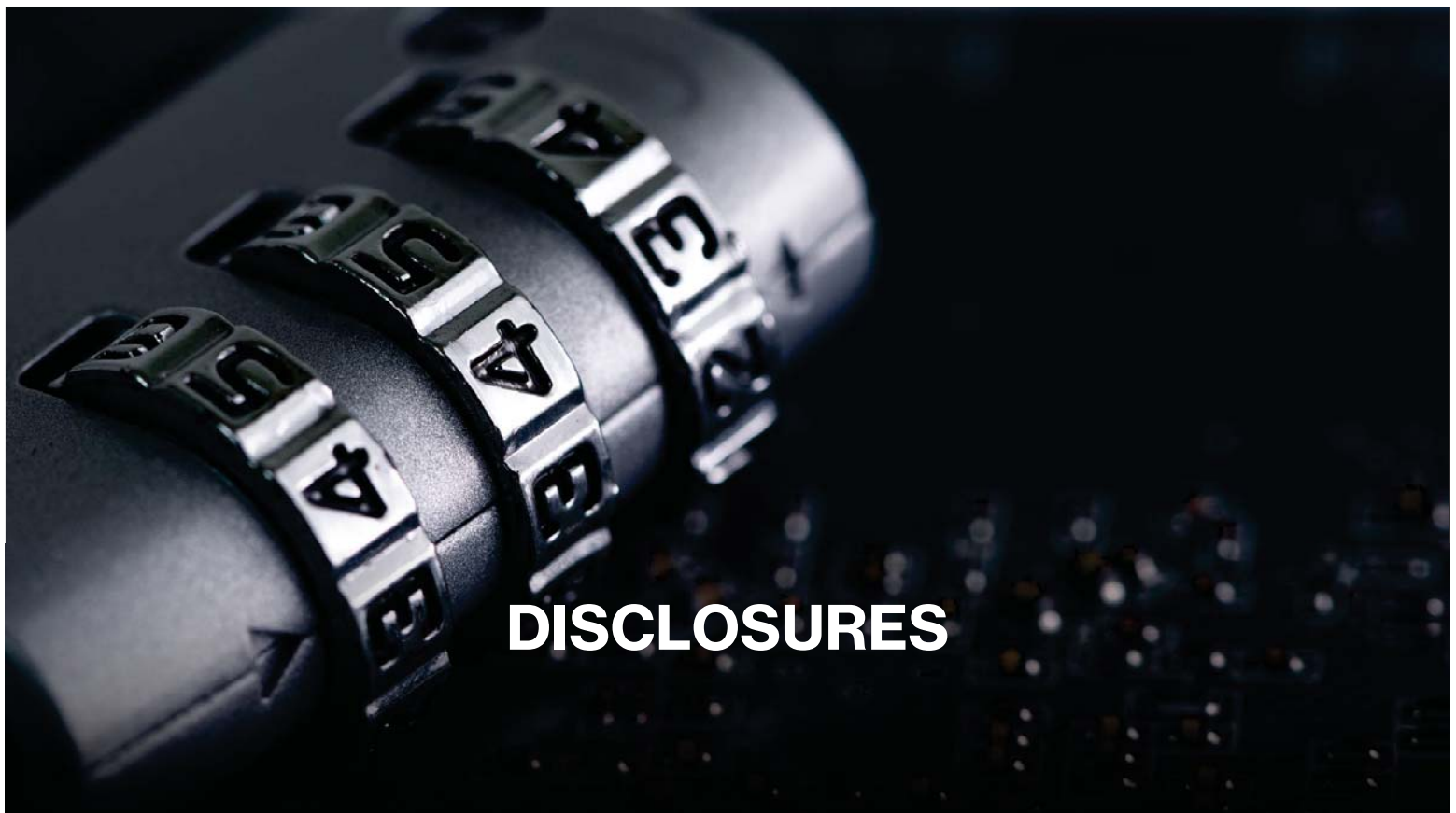ULTRASOUND GUIDED INJECTIONS OF THE SHOULDER

Dr. Arun Gupta MD, FRCPC PM&R, CSCN
EMG, Dip. Sport Medicine

- Infini Health
- University of Calgary
- CIPC April 17, 2021



Canadian INTERVENTIONAL PAIN COURSE 2021





PAIN GENERATORS

- Joints
 - AC Joint
 - Glenohumeral Joint
 - Sternoclavicular Joint
- Tendons
 - Rotator Cuff
 - Biceps Tendon
- Dynamic Pathology
 - Impingement
 - Instability
 - Capsular
- Labrum
- Referred Pain
 - Cervical Spine
 - Biomechanics



More Than Meets The Eye



- AC Joint
 - Meniscal Extrusion
 - Osteoarthritis
 - Separation
- Glenohumeral Joint
 - Osteoarthritis
 - Adhesive Capsulitis
- Sternoclavicular Joint Dysfunction
 - Inflammatory Arthropathy
- Rotator Cuff
 - Tear
 - Tendinopathy
 - Calcific Tendinosis
- Biceps Tendon
 - Subluxation/Dislocation
 - Tendinopathy (Tendinosis/Tenosynovitis)
 - Tears
- Impingement
 - External
 - Internal
- Capsule
 - Instability and Laxity – Unilateral vs Bilateral
- Labrum
 - Tear
 - Para-labral Cyst
- Other
 - Referred Pain for C-Spine
 - Radiculopathy
 - Scapular Dyskinesis
 - Posture
 - Thoracic Outlet Syndrome
 - Neuromuscular Disorders

CASE PRESENTATIONS

Where is the pain?
How do you treat it?

INJECTIONS OF THE SHOULDER

Summary: Most Common Pathology

Bursitis

- Sub-acromial/Sub-deltoid Injection

Joint Osteoarthritis

- Intra-articular Joint Injection
- Neurotomy

Tendinosis

- Needle Fenestration (Tenotomy)

Adhesive Capsulitis

- Anterior Hydrodilation

CASE 1 – LATERAL SHOULDER PAIN

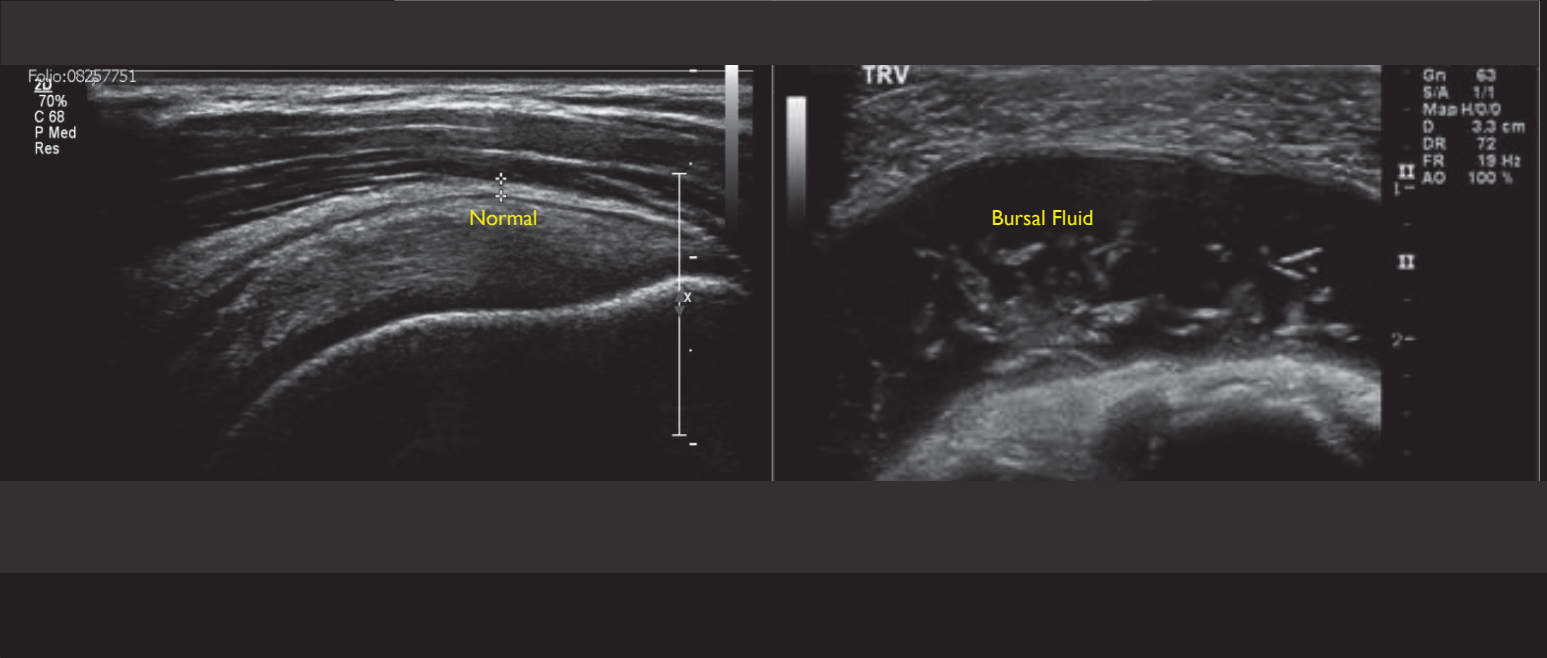
HISTORY - 34 YO FEMALE HAIRDRESSER

- Onset: Gradual over last 3 months
- Location: Lateral shoulder
- Trauma/Activity: None
- Aggravated: Cutting hair
- Alleviated: Advil
- Functional Limits: Sleep, especially on affected side
- Treatments: None

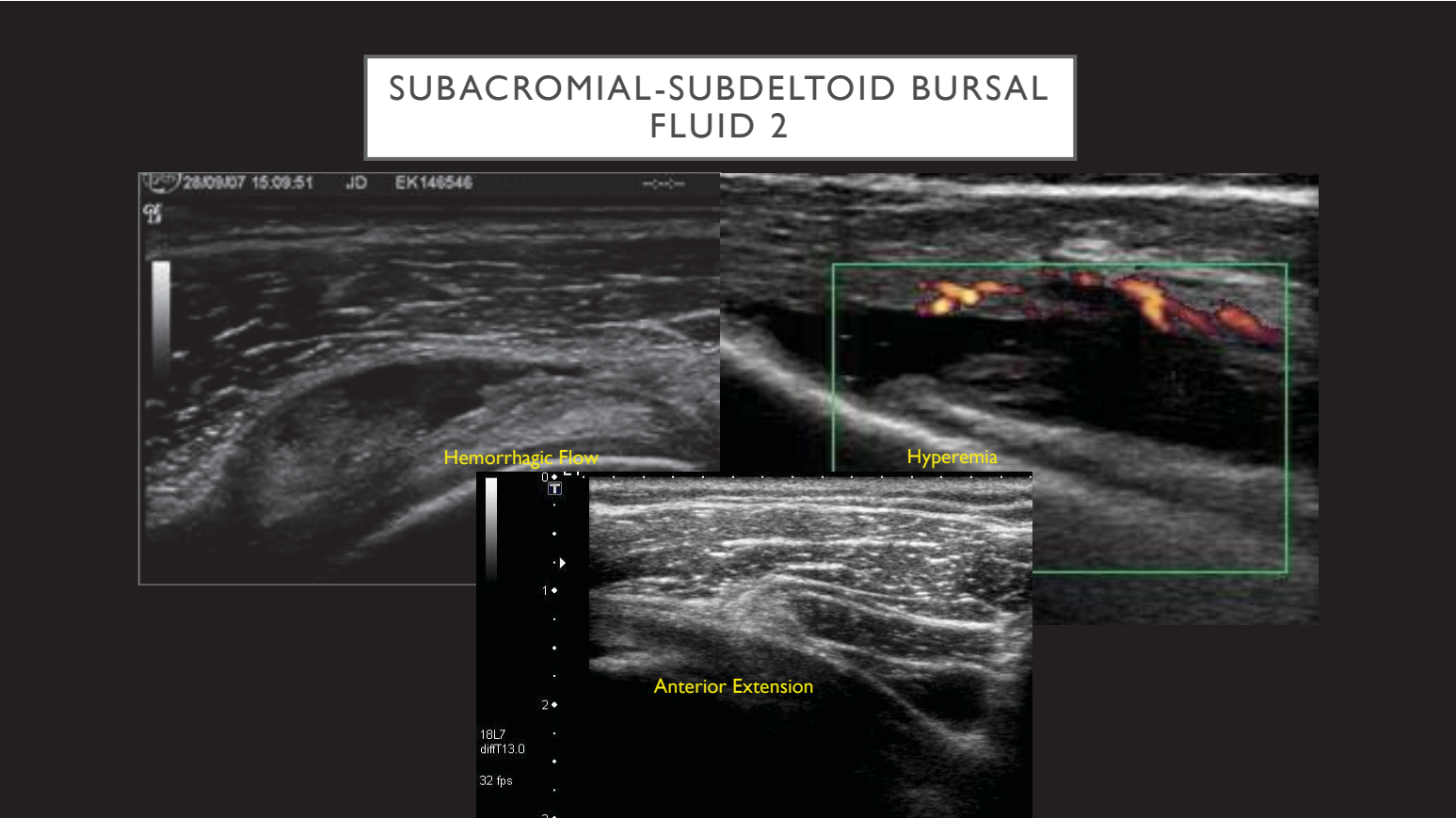
PHYSICAL EXAM

- Observation: Overweight
- ROM: Painful arc, Limited Abduction with pain but full ROM
- Neurological: Normal
- Posture/Scapula: Scapular Dyskinesia, Protraction
- Palpation: Pain over superior lateral shoulder
- Special Test: Positive Neers and Hawkins-Kennedy

SUBACROMIAL-SUBDELTOID BURSAL FLUID



SUBACROMIAL-SUBDELTOID BURSAL FLUID 2



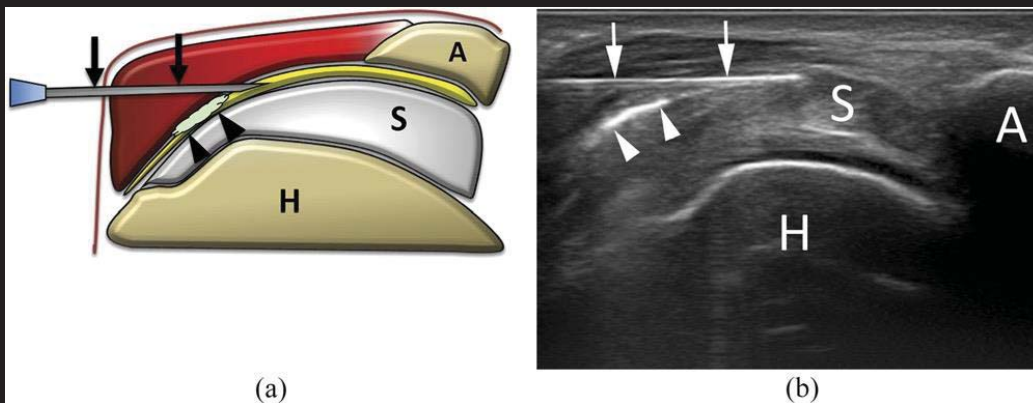
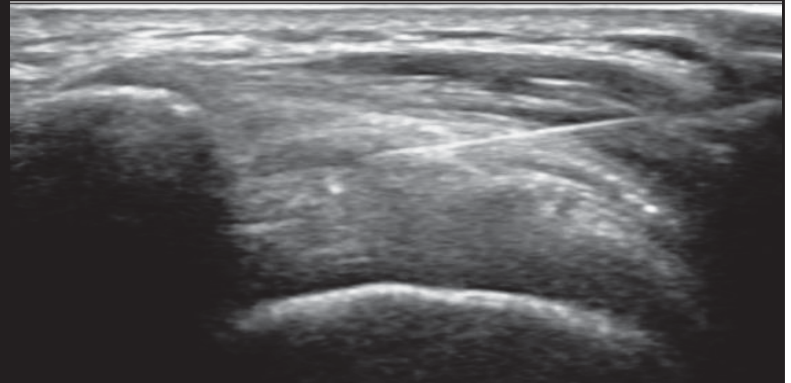
IMPINGEMENT – TREATMENT

SA/SD BURSITIS

Multimodal

- Rehabilitation
 - Shoulder and Scapular Training
- Medications
 - NSAIDS
- **Intervention**
 - **Corticosteroid**
- Surgery
 - Rare – If persistent consider bursectomy
 - May consider if treating other disorders

INJECTION



SUB-ACROMIAL/SUB-DELTOID BURSA INJECTION

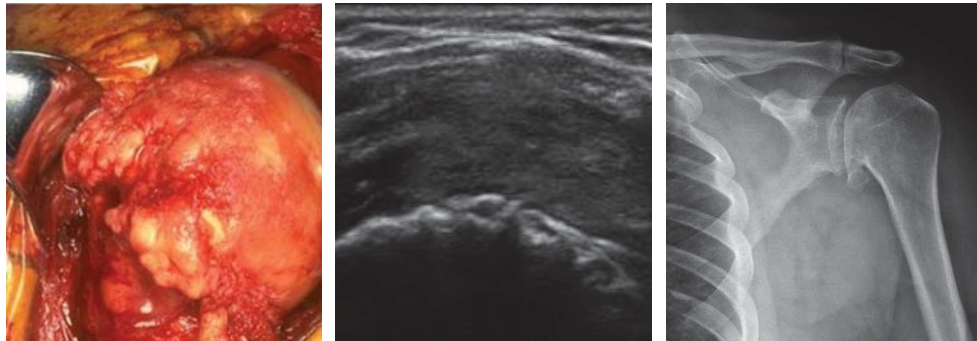
CASE 2 – DIFFUSE SHOULDER PAIN

HISTORY – 55 YO MALE
RETIRED FOOTBALL PLAYER

- Onset: Gradual over last 6 months
- Location: Diffuse shoulder
- Trauma/Activity: None
- Aggravated: Movement all planes
- Alleviated: Advil
- Functional Limits: All activities
- Treatments: None

PHYSICAL EXAM

- Observation: Muscular build
- ROM: Painful arc, Limited ROM
- Neurological: Normal
- Posture/Scapula: Scapular Dyskinesia
- Palpation: Pain over posterior shoulder
- Special Test: Pain with all movement and restriction secondary to limited ROM



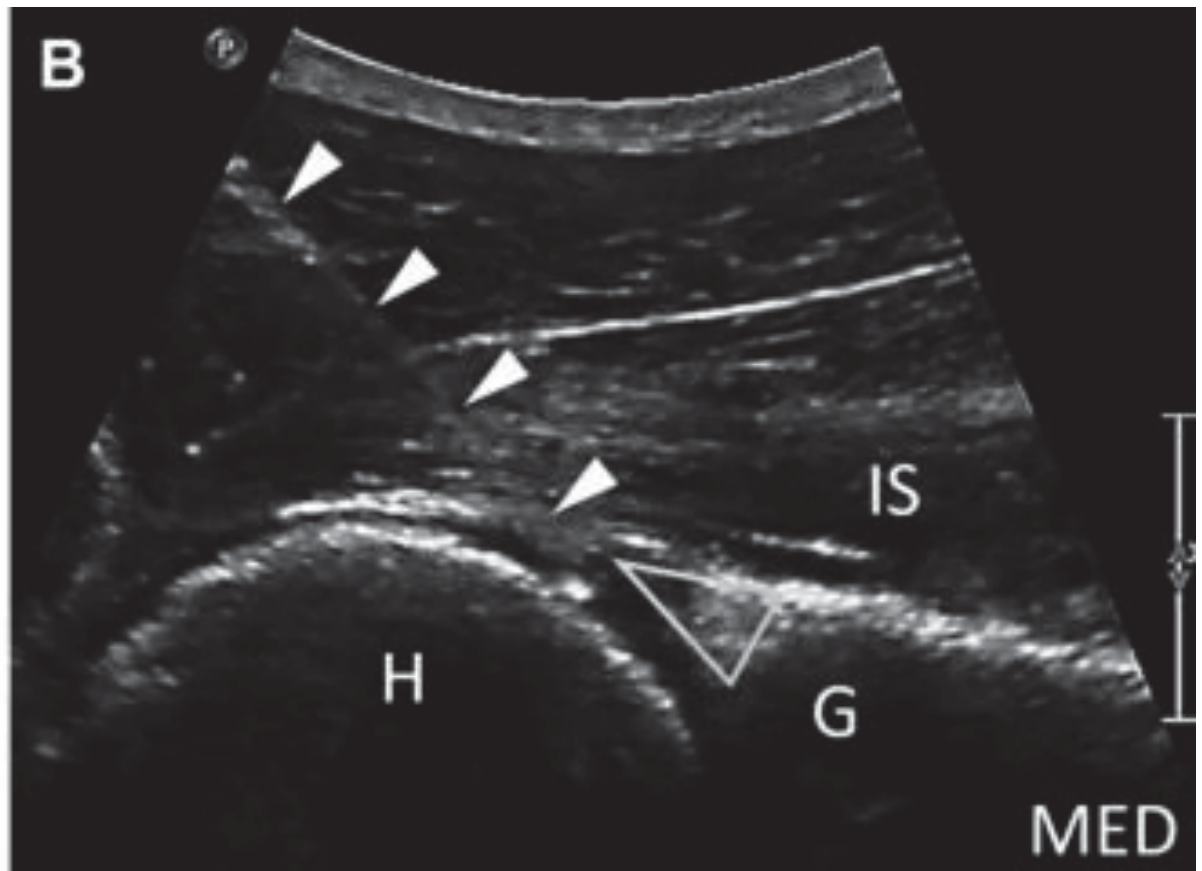
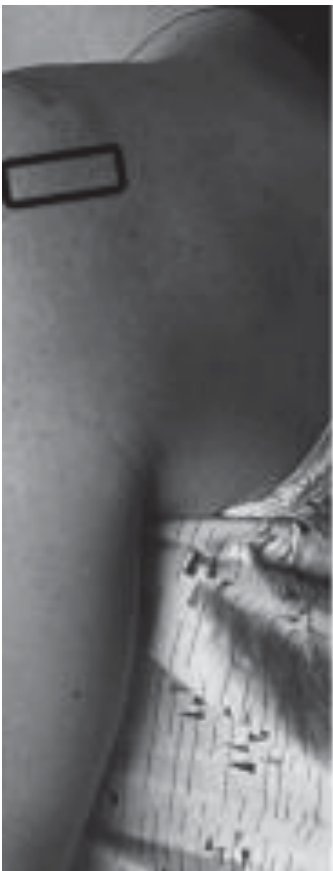OSTEOARTHRITIS

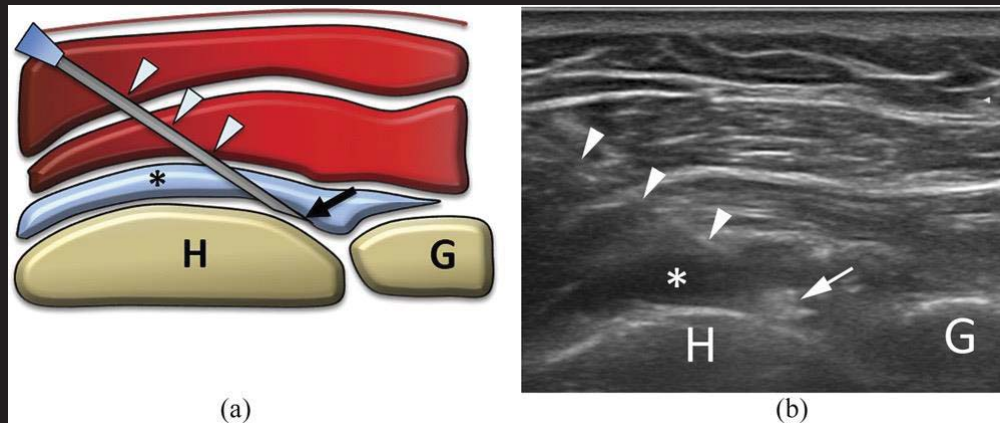
OSTEOARTHRITIS –TREATMENT

MULTIMODAL

- Rehabilitation
 - Shoulder and Scapular Training
 - Stretch Ant. Chest Wall
- Medications
 - NSAIDS
- Intervention
 - Corticosteroid
 - Viscosupplement
 - Regenerative Tech.
 - Ablation
- Surgery
 - Shoulder Replacement

OPTIONS





INTRA-ARTICULAR GLENOHUMERAL JOINT INJECTION

Messina C, Banfi G, Orlandi D, Lacelli F, Serafini G, Mauri G, et al. Ultrasound-guided interventional procedures around the shoulder. Br J Radiol 2016; 89: 20150372

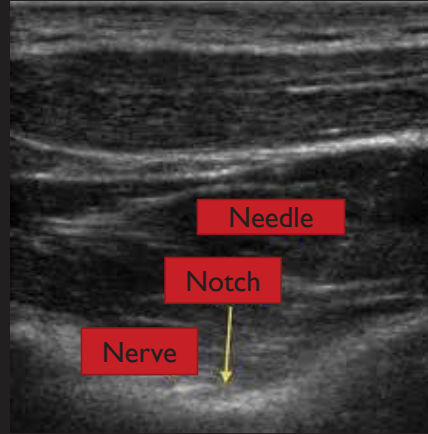
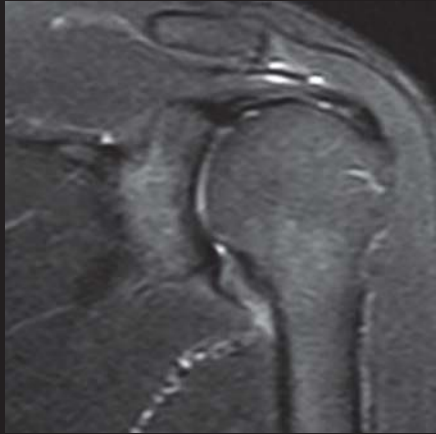CASE 3 – DIFFUSE SHOULDER PAIN

HISTORY – 56 YO FEMALE PRINCIPAL

PHYSICAL EXAM

- | | |
|--|---|
| <ul style="list-style-type: none"> • Onset: Gradual pain in diffuse shoulder • Location: Diffuse • Trauma/Activity: None. • Aggravated: All motions • Alleviated: None • Functional Limits: ADL's • Treatments: Physiotherapy ROM | <ul style="list-style-type: none"> • Observation: Holds shoulder close to body • ROM: Significant lost in external rotation, abduction and internal rotation • Neurological: Normal • Posture/Scapula: Scapular Dyskinesia • Palpation: Pain diffuse • Special Test: Normal |
|--|---|

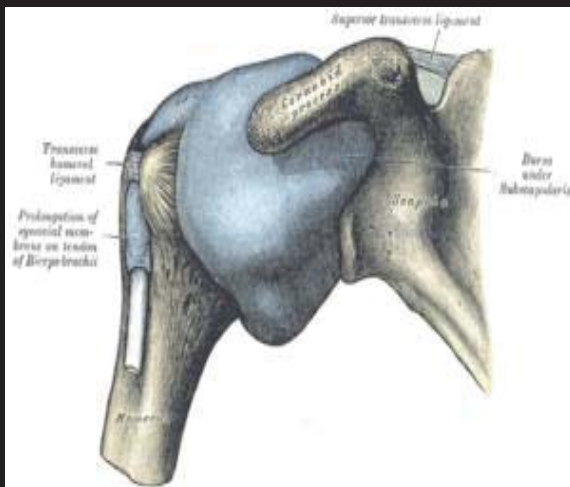
ADHESIVE CAPSULITIS



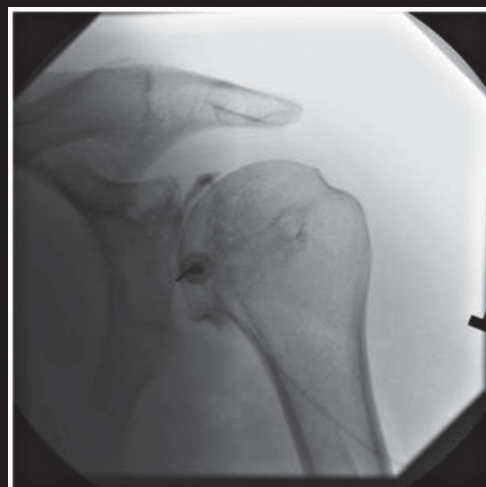
Case courtesy of Dr Noyan Zenger, Radiopaedia.org, rID: 12744

ADHESIVE CAPSULITIS

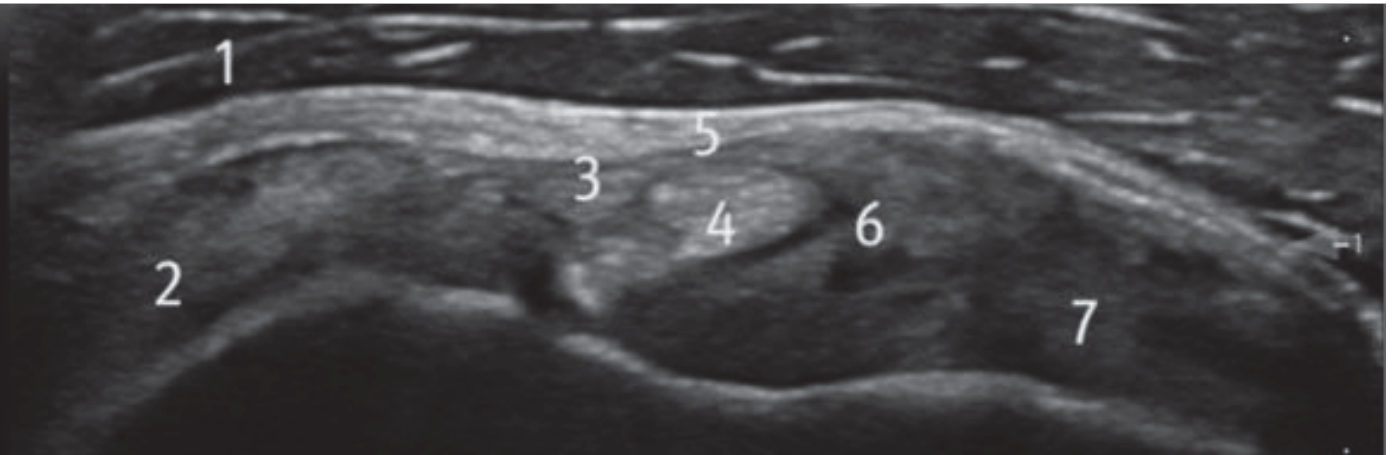
CAPSULAR DISTENTION



GLENO-HUMERAL JOINT



PH12
DR 110
FR 27
D 25 / G 50



1-deltoid

2-supraspinatus tendon

3- lateral coracohumeral ligament

4-long head biceps tendon

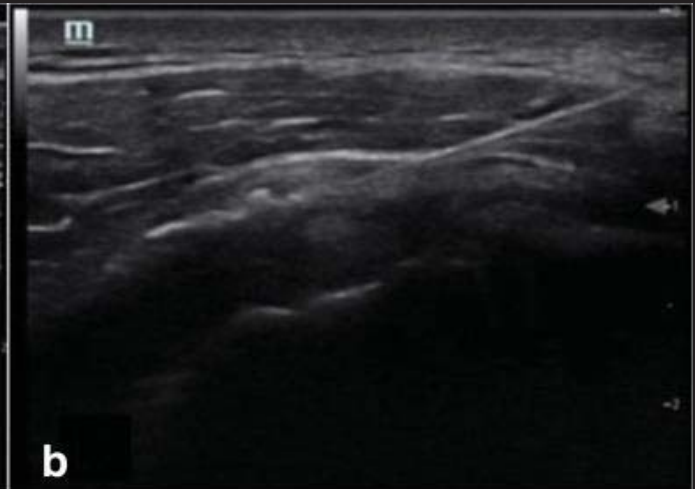
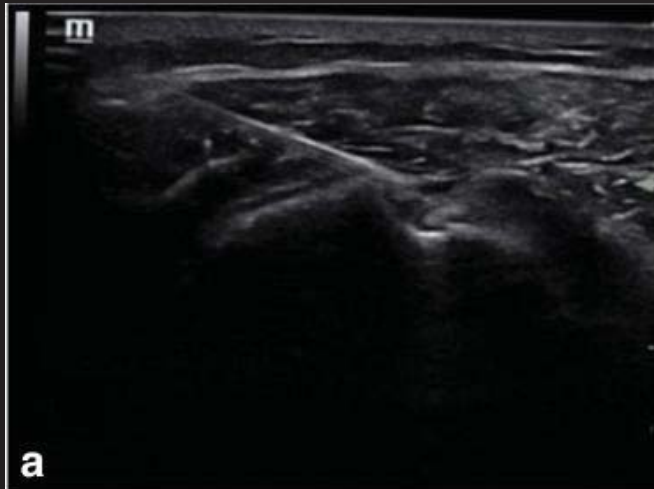
5-coracohumeral ligamen

6-sup,gleno,hum lig.

7-supscapularis tendon -2

•Elnady B, Rageh EM, Hussein MS, Abu-Zaid MH, Desouky DE, Ekhouly T, Rasker JJ. Clin Rheumatol. 2020 Dec;39(12):3815. doi: 10.1007/s10067-020-05461-1.PMID: 33058035

Frame:1/1



Elnady B, Rageh EM, Hussein MS, Abu-Zaid MH, Desouky DE, Ekhouly T, Rasker JJ. Clin Rheumatol. 2020 Dec;39(12):3815. doi: 10.1007/s10067-020-05461-1. PMID: 33058035

ADHESIVE CAPSULITIS – TREATMENT

ADHESIVE CAPSULITIS

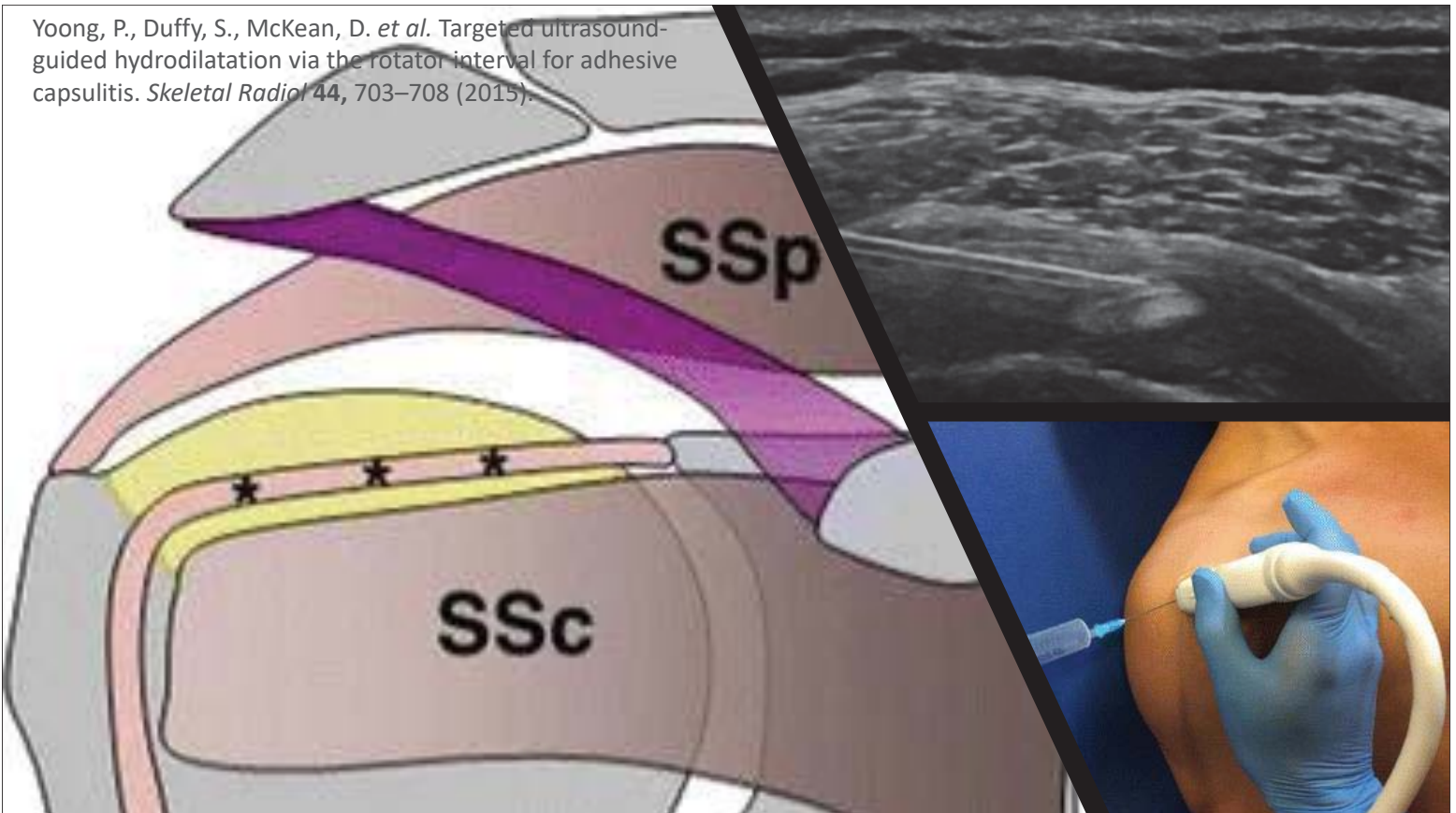
Multimodal

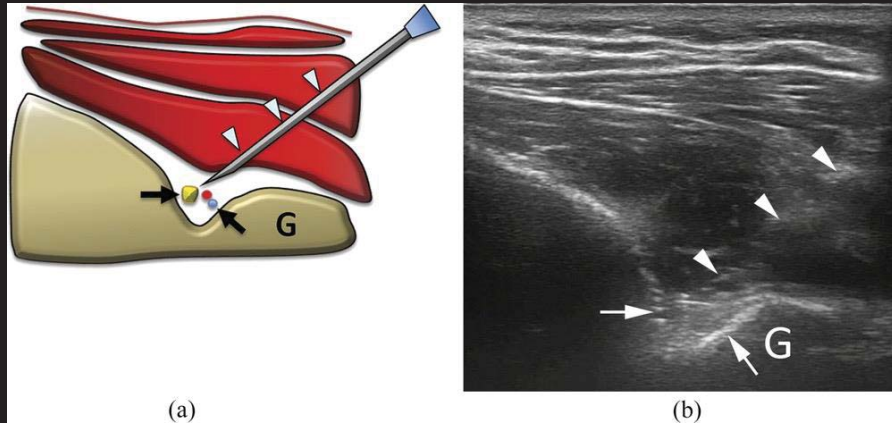
- Rehabilitation
 - Gentle range of motion exercises
- Medications
 - Pain control
- Intervention
 - Multiple
- Surgery
 - Rare – If persistent consider manipulation under anesthetic

INJECTION

- Intra-articular glenohumeral joint
- Supra-scapular nerve block
- Anterior hydrodilatation at the rotator interval
- Capsular distension

Yoong, P., Duffy, S., McKean, D. *et al.* Targeted ultrasound-guided hydrodilatation via the rotator interval for adhesive capsulitis. *Skeletal Radiol* 44, 703–708 (2015).





SUPRASCAPULAR NERVE BLOCK

Messina C, Banfi G, Orlandi D, Lacelli F, Serafini G, Mauri G, et al.
 Ultrasound-guided interventional procedures around the shoulder. Br J
 Radiol 2016; 89: 20150372.

CASE 4 – ANTEROLATERAL SHOULDER PAIN

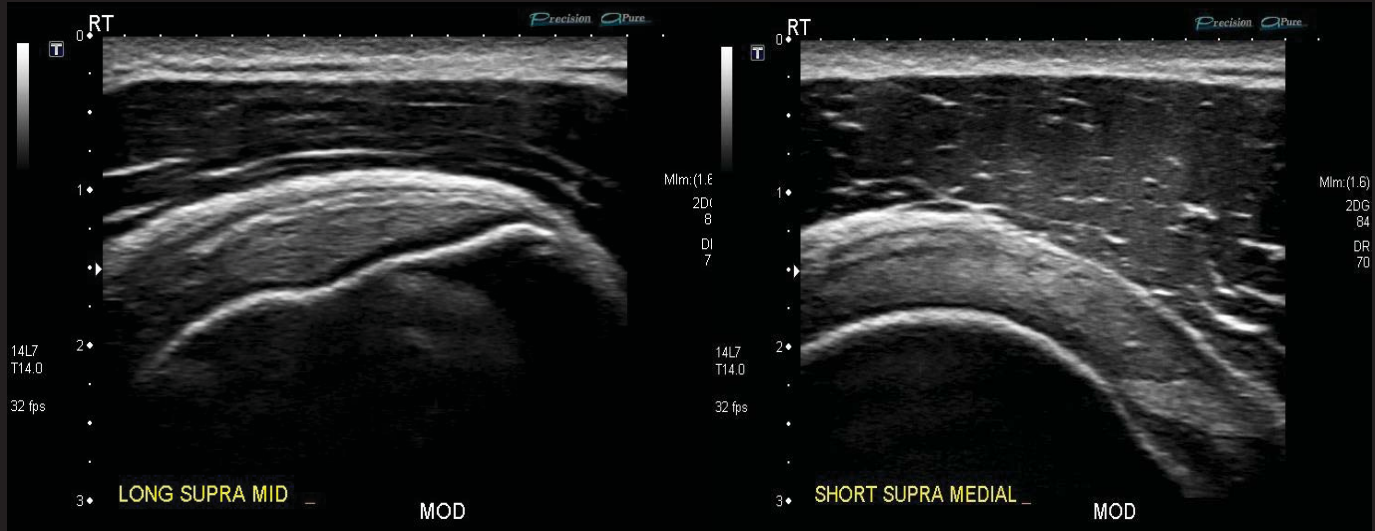
HISTORY – 28 YO MALE ENTREPRENEUR

- Onset: Acute pain while weight lifting, now over 6 months
- Location: Lateral shoulder
- Trauma/Activity: Lost control of weight tried to catch it
- Aggravated: Abduction – Forward flexion
- Alleviated: Advil and Tramacet
- Functional Limits: Able to work through the pain
- Treatments: None

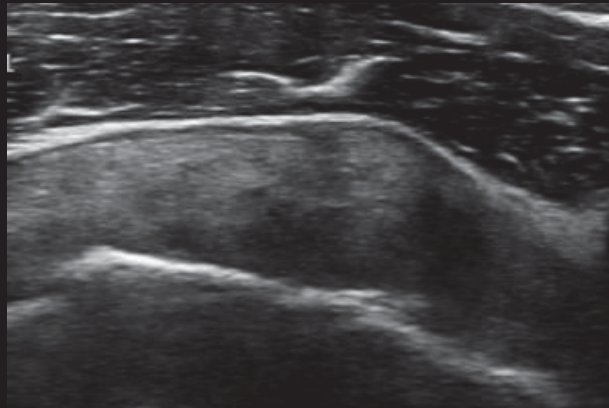
PHYSICAL EXAM

- Observation: Mild lost deltoid contour
- ROM: Painful arc, Limited Abduction with pain but full ROM
- Neurological: Normal
- Posture/Scapula: Scapular Dyskinesia, Protraction
- Palpation: Pain over lateral shoulder
- Special Test: Normal

NORMAL SUPRASPINATUS



TENDINOSIS

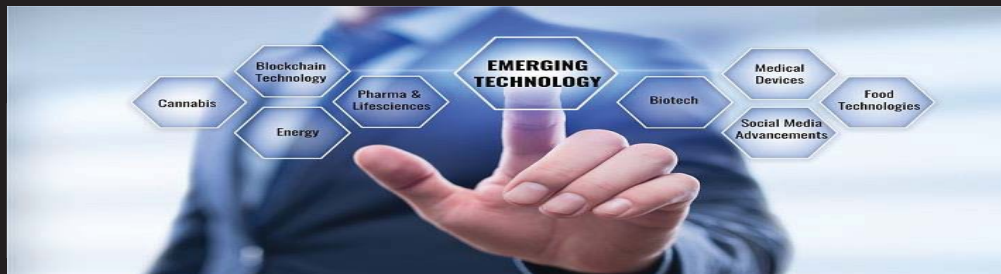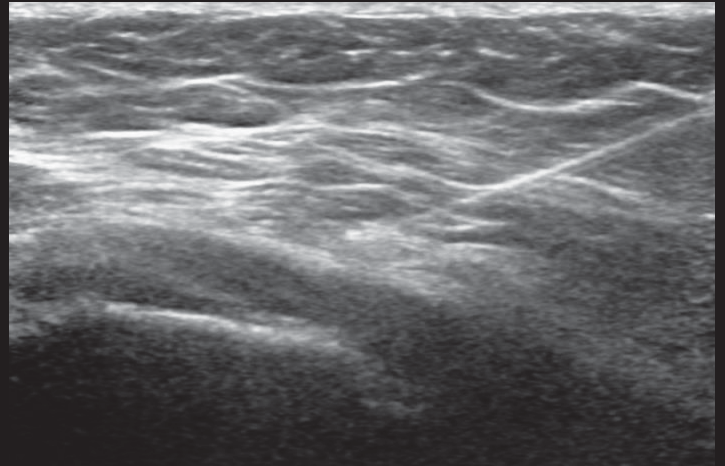


SUPRASPINATUS TENDINOSIS – TREATMENT

MULTIMODAL

- Rehabilitation
 - Rotator Cuff and Scapular Training
- Medications
 - NSAIDS, Tramacet
- Intervention
 - Corticosteroid
 - Regenerative Tech - Tenotomy
- Surgery
 - Tendinosis – Extremely Rare

INJECTION TENOTOMY



DEVICES

- Methods to remove damaged tenocytes.
 - Vajapey S, Ghenbot S, Baria MR, Magnussen RA, Vasileff WK. Utility of Percutaneous Ultrasonic Tenotomy for Tendinopathies: A Systematic Review. Sports Health. 2020 Nov PMID: 33252310.

TECHNIQUES

- Pulsed-radiofrequency Ablation For Shoulder Pain.
 - Orhurhu V, Akinola O, Grandhi R, Urits I, Abd-Elseyed A. Radiofrequency Ablation for Management of Shoulder Pain. Curr Pain Headache Rep. 2019 Jul 10;23(8):56. PMID: 31292738.

TAKE HOME

ADDITIONAL REFERENCES

In shoulder adhesive capsulitis, ultrasound-guided anterior hydrodilatation in rotator interval is more effective than posterior approach: a randomized controlled study. Elnady B, Rageh EM, Hussein MS, Abu-Zaid MH, Desouky DE, Ekhoully T, Rasker JJ. *Clin Rheumatol*. 2020 Dec;39(12):3805-3814. doi: 10.1007/s10067-020-05131-2. Epub 2020 May 8. PMID: 32385765

Yoong P, Duffy S, McKean D, Hujairi NP, Mansour R, Teh JL. Targeted ultrasound-guided hydrodilatation via the rotator interval for adhesive capsulitis. *Skeletal Radiol*. 2015 May;44(5):703-8. doi: 10.1007/s00256-014-2047-7. Epub 2014 Nov 21. PMID: 25412709.

Galloway MT, Lalley AL, Shearn JT. The role of mechanical loading in tendon development, maintenance, injury, and repair. *J Bone Joint Surg Am* 2013; 95(17) 1620-1628

Jacobson JA, Kim SM, Brigido MK. Ultrasound-Guided Percutaneous Tenotomy. *Semin Musculoskelet Radiol*. 2016 Nov;20(5):414-421. doi: 10.1055/s-0036-1597545. Epub 2016 Dec 21. PMID: 28002863.