

# Management of common pediatric skin problems

McGill Drug Therapy Course

Dr Catherine C. McCuaig

Clinical Professor

May 6, 2022

*No pertinent conflicts of interest*



## Management of common pediatric skin problems

### Learning objectives

1. Have fun
2. Witness the revolution in therapeutics
3. Review the latest options in pediatric dermatology

Interventions in kids, atopic dermatitis, psoriasis, alopecia areata, Vascular anomalies

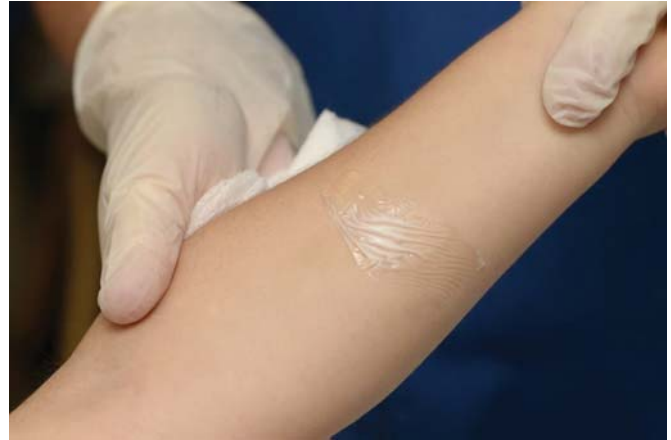

# Pearls for painless interventions

## LOCAL ANESTHESIA UNDER OCCLUSION

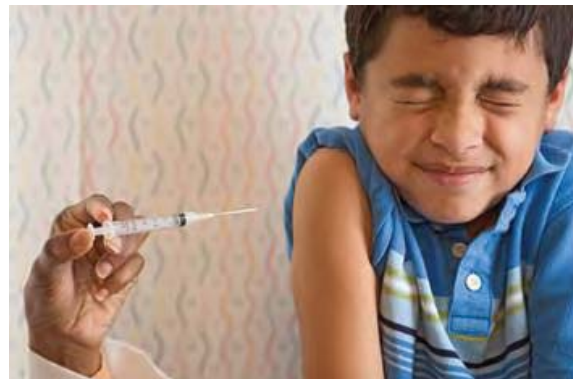

Lidocaine 5% or lidocaine 2.5-prilocaine 2.5  
Respect limited surface area ( due to absorption)



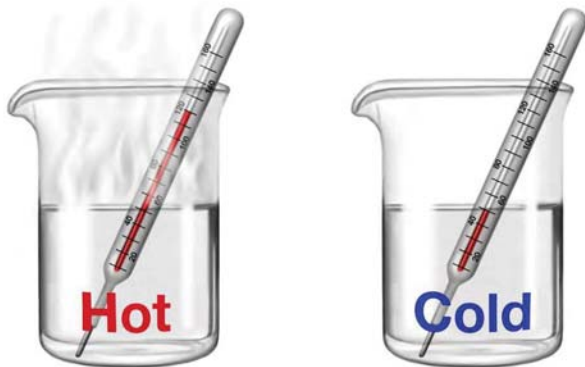
# Pearls for painless biopsies

- Do not mention NEEDLE
- Prepare your biopsy tray ahead of time and cover it up
- Block the child's view



## Pearls for painless biopsies

- Speak in a language the child understands



acne.org

- Explain time limits 10 seconds
- Play 'the statue'



## Pearls for painless biopsies

### DIVERSION!

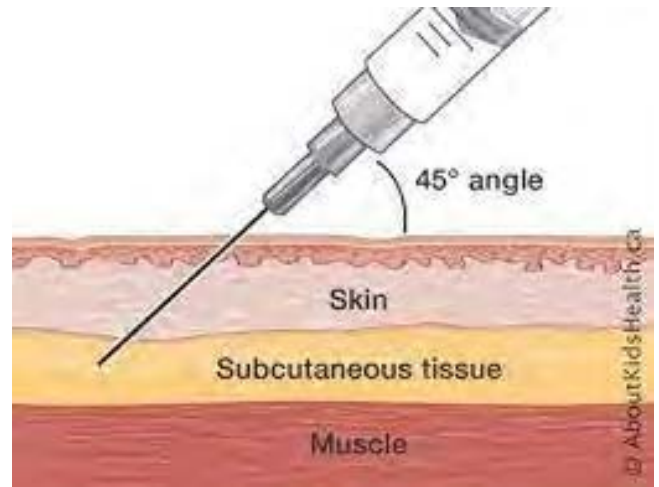
- I phone or I pad
- The child chooses a film they can watch during the procedure



CHOP

## Pearls for painless biopsies

- Go deep with lidocaine injection, in the subcutaneous tissue first before going dermal



Aboutkidshealth.ca

Roerden A. Tumescent local anesthesia in dermatologic surgery in infants. J Dtsch Dermatol Ges. 2021 Mar;19(3):352-357

## Pearls for painless biopsies

REWARD!

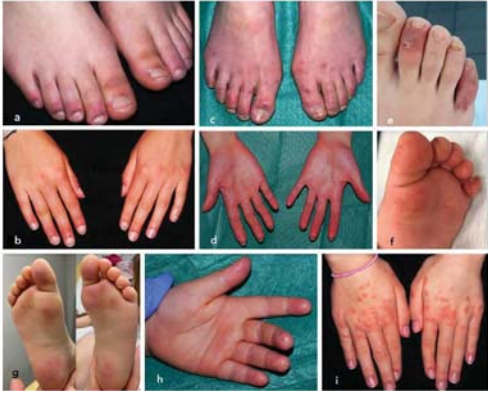

Agim NG. Pearls for Dermatologic Surgery in Pediatric Patients. Dermatol Clin. 2019;37(3):387-395.

# COVID-19 in children

## Covid toes, chilblains, perniosis


Lasts 47d; PCR, Abs usually negative



Ladha MA, ..., Ramien ML. *JCMS* 2020 Sep. Sachdeva M, ... Corales, Sibbald C. *Adv Skin Wound Care*. 2021 Mar. Kashetsky ... Bergman J. *JCMS* 2021 Apr. Hubiche T., Piram M, McCuaig C... *Ann Dermatol Venereol*. 2021 Jun

- 2+ organs involved, similar to Kawasaki but older (9yrs), Blacks Hispanics, more GI, obese US: 2617 cases, 33 deaths ( mortality 2%)

**Multisystem Inflammatory Syndrome in children (MIS-C)**

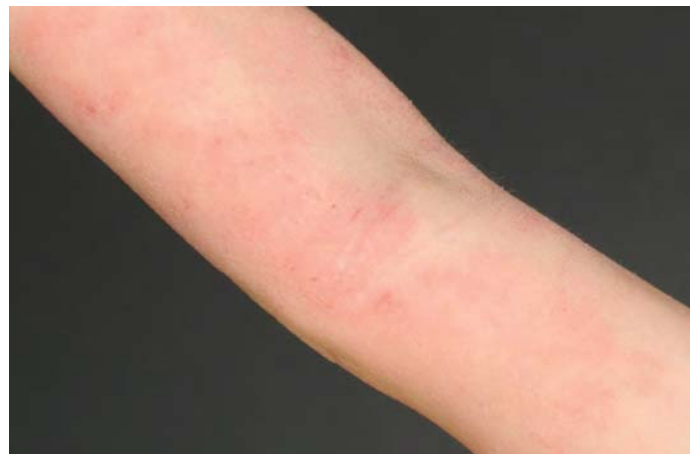
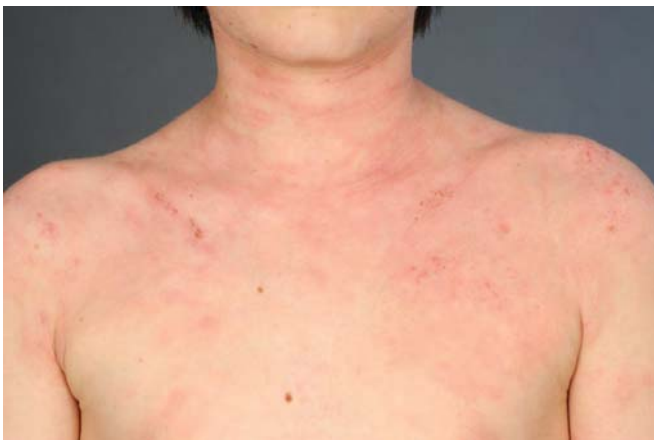
- COVID-19: 29% PCR+, 54% serology +
- 35 children
- 2 hospitals in NYC
- Kawasaki-like presentation: variable presentation
  - conjunctival injection
  - palmoplantar erythema
  - periorbital erythema/ edema
  - strawberry tongue
  - malar erythema
- GI illness common, some CV. No thrombotic events

Reference: Young T et al. *JAMA Dermatology*. Online December 9, 2020

JAMA Dermatology 8

# Resistant atopic dermatitis

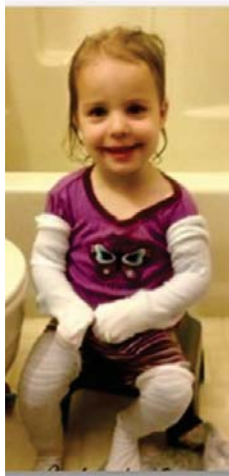




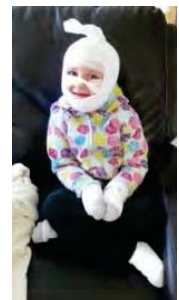## Take HOME Message: ALLERGEN?

- Is there an allergen lurking at home?
  - Pet
  - Food
  - Contact allergy

## 'Wet Wraps' are BACK



Wet compresses (Tubifast®)  
Or wet pyjamas



## Rapid, successful treatment of atopic dermatitis recalcitrant to topical corticosteroids

Daniel J. Lewis BA<sup>1,2,3</sup>  | Steven R. Feldman MD, PhD<sup>3,4,5</sup>

Used the corticosteroid ointment 'sparingly' in a thin layer  
Stopped once AD flared!!!

### ADHERENCE!

1/3 patients do not fill their prescriptions  
2/3 that do: adherence is 32% after 8 weeks.

Lewis DJ, Feldman SR. . *Pediatr Dermatol.* 2018 Jan 4.

## Therapy of atopic dermatitis

1. Make sure you have the right diagnosis
2. Hydrate hydrate hydrate
3. Address possible allergens
4. Ensure compliance

Xu X, Smartphone App JMIR Mhealth Uhealth. 2020 Oct.  
Schlessinger J. Crisaborole *Am J Clin Dermatol.* 2020 Apr.  
Draelos ZD. *J Am Acad Dermatol.* 2020

## Therapy of atopic dermatitis

4. Corticosteroids are the backbone of therapy: Steroidophobia:

**Please do not apply a thin layer!**

**And use an appropriate strength.** Hydrocortisone 1% rarely cuts it!

5. Crisaborole safe: 3 -24 mos

6. Calcineurin inhibitors continue to be an excellent choice for the face and folds

7. The biologics are here

8. The Jak inhibitors too.

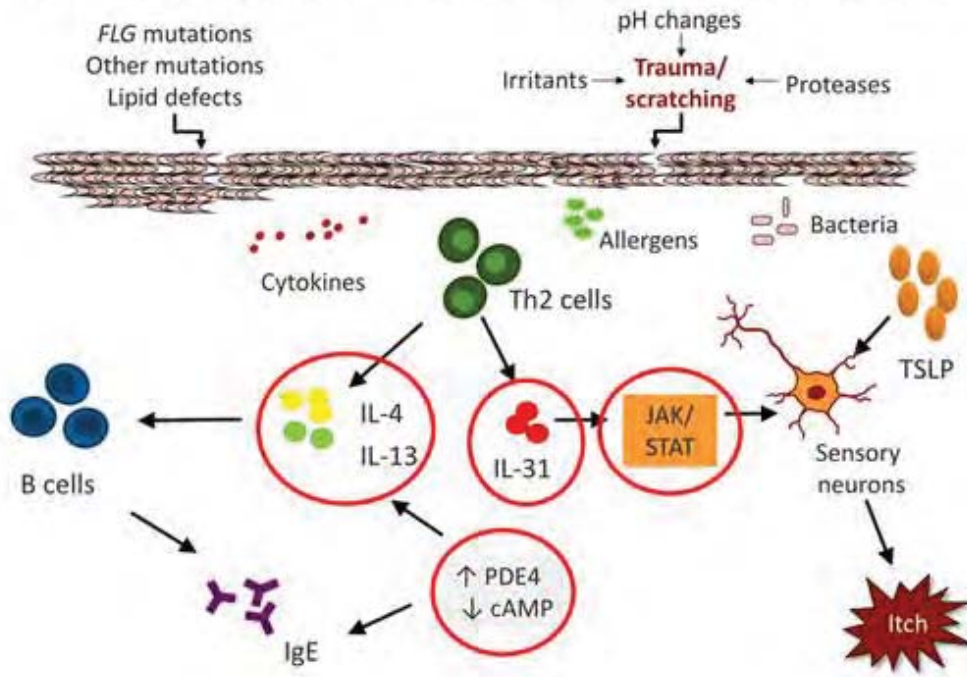
## Therapy of atopic dermatitis: Immunosuppressants & Phototherapy

- Prednisone 0.5-1 mg/kg/d Brief Tx; or triamcinolone IM at the same time as an immunosuppressant at the beginning; rebound
- Cyclosporine 5 mg/kg/day in 2 doses, rapidly ↓3 mg/kg/day 6-12 months max
- Mycophenolate mofetil 40mg/kg/day (max 500-1gm bid)
- Methotrexate 0.4-0.7 mg/kg/wk slow (3 months) but average efficacy
- Azathioprine 1-3 mg/kg/day not often prescribed

Vermeulen FM The European TREATment of ATopic eczema (TREAT) Registry Taskforce Br J Dermatol. 2020;183(6):1073-1082. Elsgaard S...Vestergaard C. Drug survival of systemic immunosuppressive treatments for atopic dermatitis in a long-term pediatric cohort. Int J Womens Dermatol. 2021 Jul 22;7(5Part B):708-715. Prussick L, MMF J Drugs Dermatol. 2016

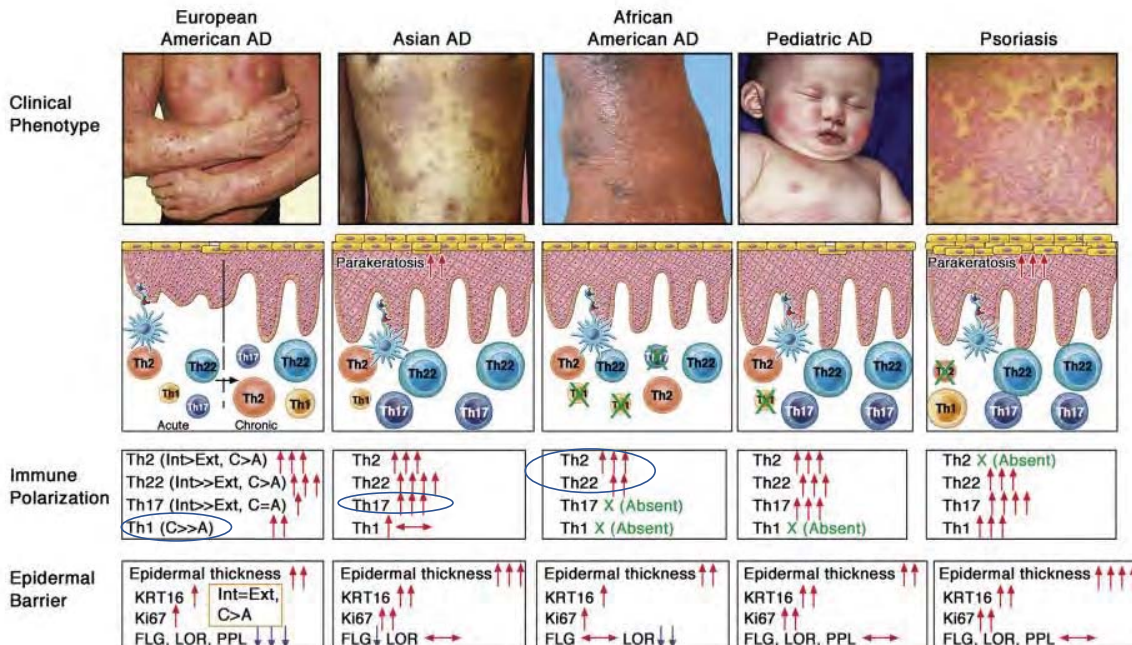


# Pathogenesis: Immune Dysregulation



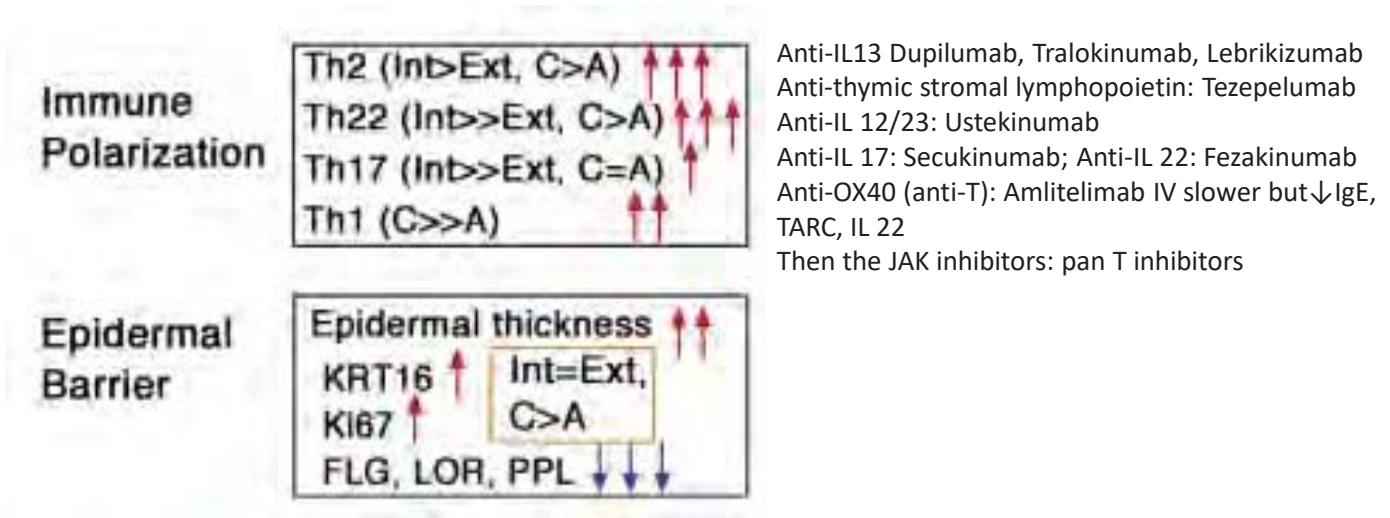
Silverberg J

## Atopic Dermatitis phenotypes & endotypes



Czarnowicki 2019

# Atopic Dermatitis phenotypes & endotypes



Anti-IL13 Dupilumab, Tralokinumab, Lebrikizumab  
 Anti-thymic stromal lymphopoietin: Tezepelumab  
 Anti-IL 12/23: Ustekinumab  
 Anti-IL 17: Secukinumab; Anti-IL 22: Fezakinumab  
 Anti-OX40 (anti-T): Amlitelimab IV slower but ↓ IgE, TARC, IL 22  
 Then the JAK inhibitors: pan T inhibitors

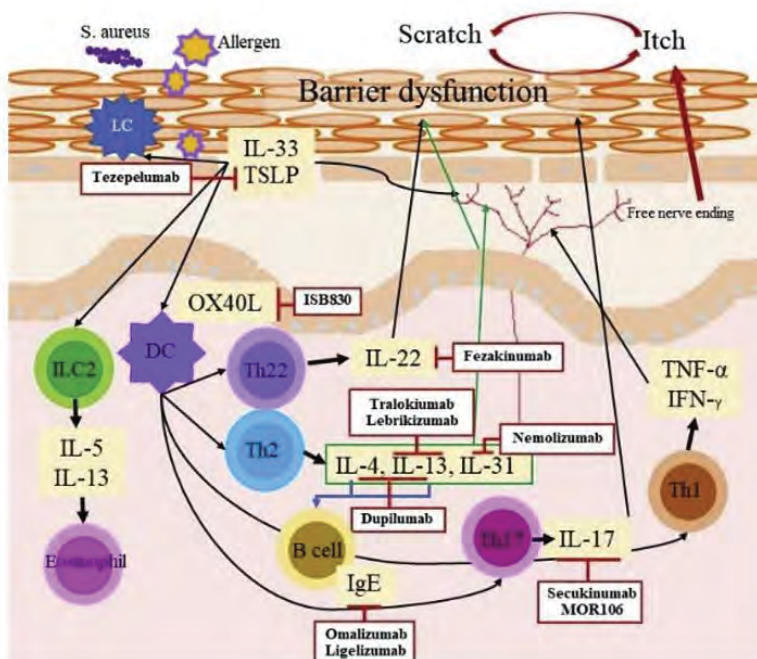
**Pruritus**

**IL-31**

Anti-IL31 Nemolizumab (better for prurigo than AD)

Czarnowicki 2019

# Biologics in Atopic Dermatitis



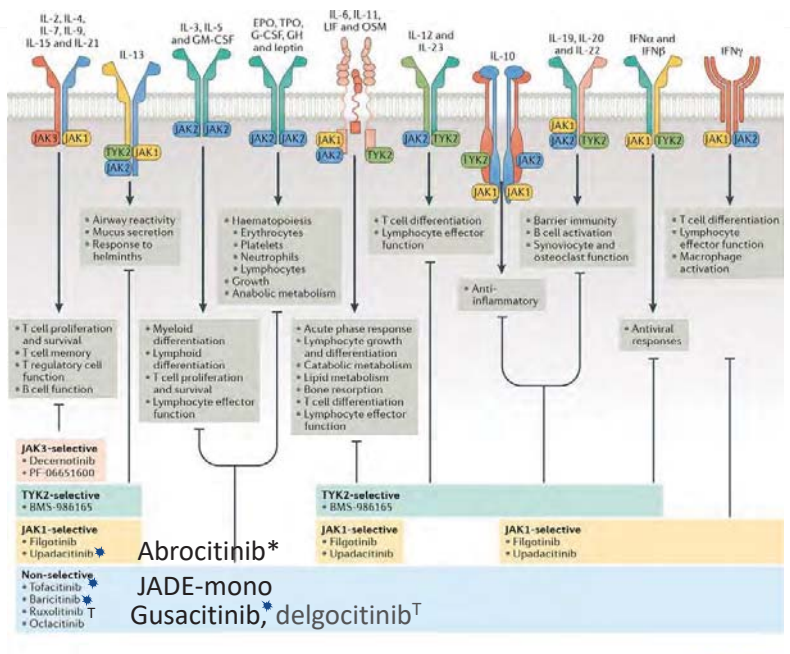
**Dupilumab** is the only current anti-IL13 approved Tx for children > 6 yrs with 300 mg SC mos. Effective in 92.9%

Paller AS. A phase 2, open-label study of single-dose dupilumab in children aged 6 months to <6 years. J EADV 2021 Feb 3 mg/kg/dose

**Anti-IL13 Tralokinumab** approved  
**Lebrikizumab** in trials;  
**Anti-IL31 Nemolizumab** dramatic anti itch  
 In trials >12 yrs of age

Ratchataswan T J Allergy Clin Immunol Pract. 2021 Mar;9(3):1053-1065.

# Jak Inhibitors in Atopic Dermatitis



Work quickly to relieve itch, effective, short  $t_{1/2}$   
 Nausea, headache, acne :lipids, CBC, CK, transaminases  
 Especially with non-selective:  
 Risk of hematologic suppression, neoplasia, infection, embolic events?

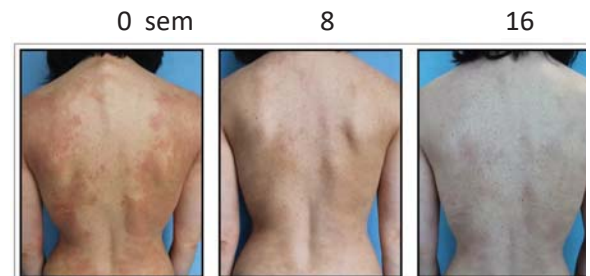Cartron AM. Clin Exp D 2021 T (AD, vitiligo)  
 Reich K. JAMA Dermatol. 2020 **Baricitinib** in trials >12 yrs of age  
 Nguyen J JAAD 2020 **upadacitinib** >6ms;  
 most promising to date, H simplex in children  
 Bieber T NEJM 2021 **Abro vs Dupi**  
 Simpson 2020 Lancet **Abrocitinib**

# Atopic Dermatitis : the biologics adverse effects

- Conjunctivitis in 10%
- Face and neck dermatitis in 5 %
- Phenotype switch form AD to psoriasis

## Atopic Dermatitis : more biologics

- **Anti-IL13 Tralokinumab** just accepted
- 600 mg then 300 mg q 2 wks
- **Anti-IL 13: Lebrikizumab** being studied
  
- **Anti-IL31 SC Nemolizumab** pruritus
- **Anti-IL-22 IV Fezakinumab**
- Anti-IL-33 IV Etokimab
- Anti-TSLP Tezepelumab
- **Anti-OX 40 IV**
- **Anti-H4R po** pruritus



Wollenberg A Br J Dermatol. 2021 Mar;184(3):437-449.  
Zhou S 2021

## Pearls for Pediatric Psoriasis

- Topicals often work well
- Phototherapy nbUVB
- Acitretin 0.25 mg/kg/day
- Methotrexate, rarely CsA
- 3 biologics approved FDA (4 yrs+ etanercept; 6 yrs+ ustekinumab, ixekizumab, secukinumab) & (adalimumab EMA)
- Apremilast (anti-PDE 4)
- Anti-IL1 anakinra, canakinumab, gevokizumab etc. , anti-IL 36 for mutations in IL36RN ( DITRA (acute GPP)) & in CARD14

Nogueira M, Paller AS, Torres T. Targeted Therapy for Pediatric Psoriasis. Paediatr Drugs. 2021  
Lansang P. J Am Acad Dermatol. 2020 Jan;82(1):213-221



# Therapeutic management in pediatric AA <sup>1</sup>: Response Rates

- **Glucocorticosteroids** Systemic (73%; 102/140), **intralesional** (75%; 211/280), and **topical** (81%; 35/43),
- **Janus kinase (JAK) inhibitors** Systemic (90%; 27/30), topical (63%; 11/17)
- **Methotrexate** (100%; 10/10)<sup>1</sup> ; Canadian study <sup>2</sup> ( <50% in 7 ) **Cyclosporine** (83%; 5/6)
- **Dupilumab** <sup>3</sup> if longstanding AD in 6 children ( AT 50% in 1; AA 85% 3/3; 0% AU 2/ 2)
- **Topical**
  - immunotherapy (54%; 187/345)
  - minoxidil (44%; 4/9)
  - anthralin (42%; 31/74)
  - calcineurin inhibitors (42%; 8/19)
- **Light modalities:**
  - 308-nm excimer laser (77%; 10/13)
  - PUVA therapy (56%; 9/16)

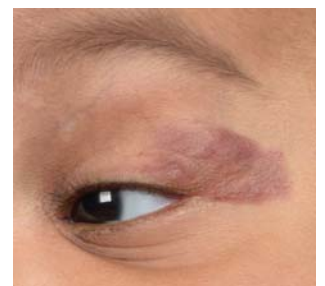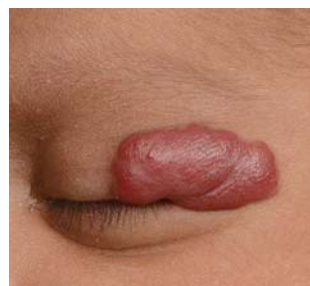1. Waśkiel-Burnat A. J Eur Acad Dermatol Venereol. 2021 Feb 25.

2 Kinoshita-Ise M,...Lansang P. Oral Methotrexate Monotherapy for Severe Alopecia Areata. J Cutan Med Surg. 2021 Mar 9

3 McKenzie PL. Dupilumab Therapy for AA in Pediatric Patients with Concomitant Atopic Dermatitis. JAAD Dermatol. 2021 Jan

## Therapy of Infantile Hemangioma

- Treat early either topical or systemic beta blocker
- Propranolol, atenolol, nadolol  
2 mg/kg/d 93% RR @ 6 mos
- Most dangerous side effect is hypoglycemia
- Topical timolol 0.5% after
- Ulceration  $\alpha$   $\uparrow$  IH size, mean time to heal 7.7 weeks even with multimodal therapy



Pam N. Dermatol Ther. 2021 Mar

Pandey V. Adverse Reactions. Indian Pediatr. 2021 Mar

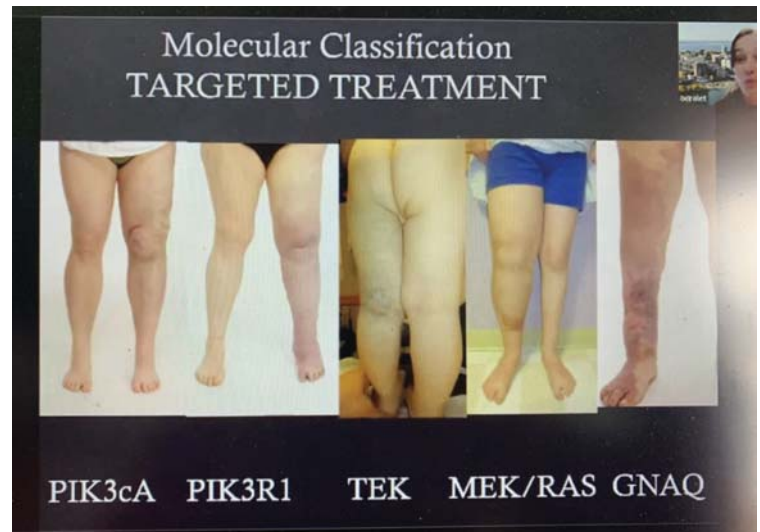Ji Y. JAMA Otolaryngol Head Neck Surg. 2021 Apr

Fernández Faith E. Ulceration in Infantile Hemangioma. JAMA Dermatol. 2021 May.



# Therapy of Vascular Anomalies courtesy of Dr B Drolet

- Sirolimus (anti-RAS)
  - Excellent results in venous & lymphatic malformations
- Alpelisib (anti-PIK3Ca)
  - Studies underway



Geeurickx M. Sirolimus J Vasc Surg Venous Lymphat Disord. 2021 Mar  
Venot Q Targeted therapy in PROS 2018

## Management of common pediatric skin problems

### Learning objectives

1. Hope you had fun
2. Witness the revolution in therapeutics based on the pathophysiology & genetics
3. Review the latest options in pediatric dermatology

Interventions in children,  
atopic dermatitis, psoriasis, alopecia areata,  
Vascular anomalies

